



A Case Report: Ruptured Testicular Seminoma in a Female with Ambiguous Genitalia, Dr. Sulman Alamin Medical Center, Elhassaheisa, Gezira State, Sudan; 2023

Khalid Adam Babiker Suleiman^{1,*}, Omer Taha Ahmed Elmukashfi²,
Taha Ahmed Elmukashfi Elshiekh³, Asma Mohammed Warrag Omer⁴

¹Hassaheisa Teaching Hospital, Ministry of Health, Elhassaheisa, Sudan

²General Surgery Council, Sudan Medical Specialization Board, Khartoum, Sudan

³Department of Community Medicine, Faculty of Medicine, University of Khartoum, Khartoum, Sudan

⁴National Cancer Institute (NCI), University of Gezira, Wadmadeni, Sudan

Email address:

khalidsurgery17@gmail.com (Khalid Adam Babiker Suleiman)

*Corresponding author

To cite this article:

Khalid Adam Babiker Suleiman, Omer Taha Ahmed Elmukashfi, Taha Ahmed Elmukashfi Elshiekh, Asma Mohammed Warrag Omer. A Case Report: Ruptured Testicular Seminoma in a Female with Ambiguous Genitalia, Dr. Sulman Alamin Medical Center, Elhassaheisa, Gezira State, Sudan; 2023. *International Journal of Medical Case Reports*. Vol. 2, No. 2, 2023, pp. 12-15. doi: 10.11648/j.ijmcr.20230202.12

Received: March 13, 2023; Accepted: May 12, 2023; Published: May 25, 2023

Abstract: Background: Ambiguous genitalia represent a sequel of sexual development disorders where the external genitalia don't have a typical resemblance to that of male or female. Methods: This was a female case of ambiguous genitalia, her age was twenty-eight years, ultrasound examination revealed atrophied uterus and bilateral undescended testes. She complained of gradual size increase of her left testicle in the last 6 months. Due to sudden trauma, she developed severe pain and swelling in her left groin. On examination: patient looked unwell, in pain, afebrile, locally there was swelling about 10 cm in size with shiny and red looking, it was very tender, otherwise it was unremarkable. So, this was considered as a case of left testicular trauma that need urgent left groin exploration. The patient was counselled and consented about possible orchidectomy. Intra-operative note: under spinal anesthesia patient was put on supine position, skin painted by yamidin, left inguinal incision was made and hematoma was evacuated, the left testicle was found to be hugely enlarged and ruptured. The spermatic cord was clamped and orchidectomy was done. No intra operative complications. Result: Histological examination of the testicular specimen confirmed that it was a germ cell tumor [Seminoma]. Patient was recommended to for: (1) Chemotherapy at the Oncology Department, (2) Laparoscopic search for her right undescended testis to confirm whether it is a testis or an ovary, (3) Buccal biopsy for sex determination and (4) Surgery, for the right side, if needed. Conclusion and recommendation: Neglected cases of undescended testis may have a serious outcome. Screening for ambiguous genitalia, and early exploration and management was highly recommended.

Keywords: Ambiguous Genitalia, Testicular Seminoma, Sudan

1. Introduction

Disorders of sex development (DSD) are identified as conditions associated with abnormal development of anatomical, chromosomal or gonadal sex. Ambiguous genitalia represent a sequel of sexual development disorders that lead to a birth defect where the external genitalia don't have a typical resemblance to that of male or female. In the past the term intersex was used for such conditions and was

classified into three subtypes: male pseudo-hermaphrodite, female pseudo-hermaphrodite and true hermaphrodite. Recently the term intersex was replaced by Disorder of Sex Development which subdivided into as 46, XX DSD; 46, XY DSD; and Sex chromosome DSD. Ambiguous genitalia are the most common clinical features of DSD [1-5]. According to the 2006 Chicago Consensus, Disorders of Sex Development (DSD) are defined as: (1) obvious ambiguous genitalia; (2) apparently female genitalia with

clitoromegaly, posterior labial fusion, or inguinal/labial mass; (3) apparently male genitalia with bilateral cryptorchidism, micro-penis, isolated perineal hypospadias, or moderate hypospadias with cryptorchidism; (4) family history of DSD; (5) discordance between genital appearance and prenatal karyotype [2, 6]. The most usual causes of ambiguous genitalia in genetic females are: congenital adrenal hyperplasia (CAH), maternal ingestion of substances with male hormone activity during pregnancy, and male hormone producing tumor in female fetus or mother; while the most common causes of ambiguous genitalia among males are: Leydig cell aplasia, 5-alpha-reductase deficiency, androgen insensitivity syndrome, and maternal ingestion of substances with female hormone activity during pregnancy [3]. Ambiguous genitalia can be also associated with Lipoid congenital adrenal hyperplasia (LCAH) [7]. In Nigeria, congenital adrenal hyperplasia (CAH) (46 XX intersex with virilization of the external genital) is the main cause of ambiguous external genitalia [8]. Among Hispanic, Slavic, Italian and European Jewish population the most common cause of ambiguous genitalia is congenital Adrenal Hyperplasia followed by mixed gonadal dysgenesis (MGD) [3]. Fausto-Sterling suggested that the incidence of Disorders of Sex Development (DSD) is 1.7% of live births in 2000; while Sax – after two years – subtracted patients without genital ambiguity, such as those with Turner and Klinefelter syndromes and the non-classical form of congenital adrenal hyperplasia that have been involved by Fausto-Sterling and reported that the incidence of DSD with genital ambiguity is 0.0018% [9]. There are no clear estimates of the incidence of ambiguous genitalia at birth, as only a proportion of individuals with these condition present difficulties with sex designation. However, incidence has been estimated at approximately one in 4,500-5,500 live births. In UK, the incidence, is estimated to be about 1 in 18,000 births in UK [3, 6]. The incidence of ambiguous genitalia found to be more in developing countries rather than the developed ones and this explained by the high rate of consanguineous marriages in the developing countries, such as Saudi Arabia which reported as 1 in 2,500 live births and in Egypt 1 in 3,000 live births, unlike in Germany which is low, i.e., 2 per 10,000 live births [1]. The global incidence of individuals with karyotype 46, XY and DSD has been estimated at 1:20,000 live births. Ovo-testicular DSD occurs in 1:100,000 live births. The incidence of 46, XX DSD primarily consisting of congenital adrenal hyperplasia (CAH) has been estimated at 1:14,000-15,000 live births [6]. To our knowledge, only 3 cases of testicular carcinoma in transgender women have been reported in the literature [10]. Ambiguous genitalia are common medical emergencies in new born that has significant impact on both (male and female), immediately after birth such as congenital adrenal hyperplasia and certain malformation syndromes that may have potential risk to child's life and in the long term, such as unresolved sex definition that may result in extreme psychosocial trauma for patients and their families,

therefore ambiguous genitalia should be treated by multidisciplinary team [1, 5, 6, 9, 11]. It is very important to interview and investigate the parents through the pregnancy history, with special attention to the use of medication and signs of maternal virilization during pregnancy and cases of low birth weight. It is also important to ask actively about family history, such as consanguinity between parents, similar cases in the family, family history of delayed or precocious puberty, infertility, hypertension in childhood, or unexplained deaths in the first months after birth [6]. The external genitalia must be evaluated for degree of virilization, considering the following: phallus size; position of the urinary meatus; presence of a vaginal introitus or opening of the urogenital sinus; degree of fusion, symmetry, pigmentation and roflation of the labio-scrotal folds; presence of inguinal masses; and the location and size of the gonads. The Prader Scale was initially designed to assess the degree of sexual ambiguity in individuals with CAH. However, in clinical practice it is often used in other cases of ambiguous genitalia. Inguinal gonads can be detected by palpation and ultrasonography (US). This can also identify intra-abdominal gonads, the uterus, and adrenal abnormalities. However, the ability of US to locate intra-abdominal ovaries and testes is limited and may require supplementation with other imaging modes, such as nuclear magnetic resonance (NMR) [6, 12]. Nowadays fetal sex can be detected by ultrasound accurately from 12 weeks of gestation onwards [4].

2. Case Report

A twenty-eight years old female - a known case of ambiguous genitalia - where pelvic U/S showed atrophied uterus and bilateral undescended testes, reported gradual increase in her left testicular size during the last 6 months. She lifted a child and, unfortunately, suddenly the child fell out of her hands into her left groin area, thereafter she developed severe pain and swelling in the left groin. On examination: patient looked unwell, in pain, afebrile, locally there was swelling about 10 cm in size with shiny and red looking, it was very tender, otherwise it was unremarkable. Investigations: Hb: 13.8g/dl, TWBCs: 8.8×10^3 , PLTs: 357×10^3 , Urea: 23 mg/dl, Creatinine: 0.7 mg/dl, U/G: clear, Na: 135 mmol/l, K: 4 mmol/l, blood group: A+ve. The diagnosis was made as left testicular trauma and the decision was urgent left groin exploration. The patient was counselled and consented about possible orchidectomy. Intra-operative note: under spinal anesthesia patient was put on supine position, skin painted by yamidin, left inguinal incision was made and hematoma evacuated, the left testicle was found to be hugely enlarged and ruptured [Figures 1 & 2]. Clamping of the spermatic cord was done and orchidectomy was performed. No intra operative complications. Specimen was sent for histopathology and the result revealed Germ cell tumor [Seminoma] [Figure 3]. Patient was planned for: (1) Chemotherapy at the Oncology Department, (2) Laparoscopic search for her right undescended testis to confirm whether it is a

testis or an ovary, (3) Buccal biopsy for sex determination and (4) Surgery, for the right side, if needed.

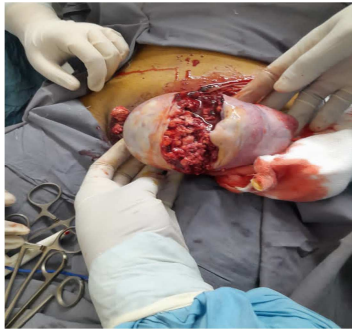

Figure 1. Intra-operative, Ruptured Testicular Seminoma, Female, Ambiguous Genitalia, Dr. Sulman Alamin Medical Center, Gezira State, Sudan; 2023.

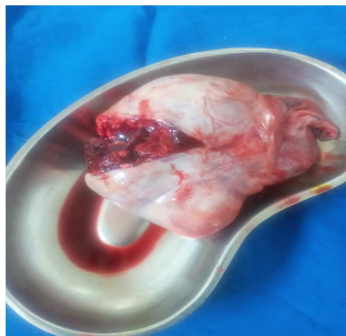

Figure 2. Ruptured testis, Testicular Seminoma, Female, Ambiguous Genitalia, Dr. Sulman Alamin Medical Center, Gezira State, Sudan; 2023.

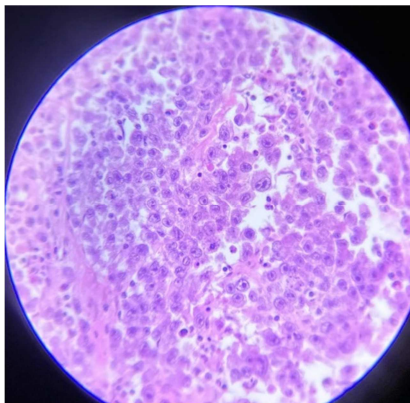


Figure 3. Histology, Ruptured Testicular Seminoma, Female, Ambiguous Genitalia, Dr. Sulman Alamin Medical Center, Gezira State, Sudan; 2023.

3. Discussion

This was a case report of 28 years old female, who was a known case of ambiguous genitalia with a history of blunt trauma to her left groin region, that led to rupture of her undescended left testis which is inconsistent with many international findings [1-15]. Testicular carcinoma is the most common malignancy among biological men aged between (15-35) years unlike what mentioned in our case report. The majority of testicular carcinoma presented as painless masses, so that absence of symptoms results in late

diagnosis as mentioned in many studies, unlike our case which was present with painful groin swelling after trauma. The reason for such pain may be due to the trauma [10]. Our case was diagnosed as ambiguous genitalia at adult life unlike many international reports. This may be due to her late seeking health advise [7]. To our knowledge, only 3 cases of testicular carcinoma in transgender women have been reported in the literature. Our case may represent the first case of testicular carcinoma reported among female with ambiguous genitalia [10].

4. Conclusion and Recommendation

Neglected cases of undescended testis may have a serious outcome. We recommended screening for ambiguous genitalia, health education, and specialized centers with multidisciplinary team for management of such cases, because it is a sensitive issue in our community.

References

- [1] Manzoor J, Aftab S and Yaqoob M, Ambiguous genitalia: An overview of 7 years' experience at the Children's Hospital & Institute of Child Health, Lahore, Pakistan, Pak J Med Sci January - February 2019, 35 (1), pp: (151-155).
- [2] Gentile M N, Lam L, Gangat M and Kogeman Y, An unusual case of ambiguous genitalia, IJCRI 2012, 3 (3), pp: (24-26).
- [3] Chowdhury M A K, Anwar R and Saha A, Ambiguous genitalia—A social dilemma in Bangladesh: A case report, International Journal of Surgery Case Reports 42 (2018), pp: (98–101).
- [4] Coşkun A, Özdemir Ö, Akdemir G, Kirank G, Antenatal Diagnosis of Ambiguous Genitalia in a Fetus at 28th Gestational Week, Gynecol Obstet Reprod Med, 13 (2), pp: (174-175).
- [5] Sabnis A, Kamale V N, Ambiguous Genitalia: A Case Report, International Journal of Science and Research, 7 (4), April 2018, pp: (114-116).
- [6] Luz C C, et al, Cases of ambiguous genitalia from a public university hospital, Residência Pediátrica; 2022: Ahead of Print, pp: (1-5).
- [7] Sheikh W H, et al, A Child with Ambiguous Genitalia: An Atypical Presentation, Journal of the College of Physicians and Surgeons Pakistan 2019, Vol. 29 (Special Supplement 1 of Case Reports), pp: (S54-S55).
- [8] Aliyu I, Microcephaly with ambiguous genitalia, Medical Journal of Dr. D. Y. Patil University, November-December 2015, 8 (6), pp: (766-768).
- [9] Paula G B D, et al, 408 Cases of Genital Ambiguity Followed by Single Multidisciplinary Team during 23 Years: Etiologic Diagnosis and Sex of Rearing, International Journal of Endocrinology Volume 2016, Article ID 4963574, 9 pages.
- [10] Elshimy G, Tran K, Harman S M, and Ricardo Correa R, Unmasked Testicular Seminoma During Use of Hormonal Transgender Woman Therapy: A Hidden hCG-Secreting Tumor, Journal of the Endocrine Society, July 2020, 4 (7), PP: (1-8).

- [11] Sowande O A, Adejuyigbe O, Management of ambiguous genitalia in ile ife, Nigeria: Challenges and outcome, African Journal of Paediatric Surgery, January-June 2009. 6 (1), PP: (14-18).
- [12] Sato T, et al, Less-Invasive Diagnostic Approaches for Infants with Suspected Differences of Sex Development: A Case Report of a 297-g Neonate with Ambiguous Genitalia, Neonatology 2022, 119, PP: (785–789).
- [13] Gargari S S, Azizi F, Saleh N, Omrani M D, A Case with late onset of ambiguous genitalia, Int J Reprod BioMed, 15 (3). pp: (175-178).
- [14] Mil E and Hiort O, Three out of four: a case discussion on ambiguous genitalia, European Journal of Endocrinology 2008, 159, PP: (S91–S93).
- [15] Ng S F, Boo N Y, Wu L L, Shuib S, A rare case of ambiguous genitalia, Singapore Med J 2007; 48 (9), PP; (858-861).